Check for updates

Distal Tibiofibular Syndesmosis Injuries in the National Football League (NFL): A Spectrum of Pathology That Correlates With Time to Return to Full Participation

Andrew W. Kuhn, MD, Michael J. Coughlin, MD, Shane J. McGonegle, MD, Mackenzie M. Herzog, PhD, MPH, Nate Weir, MS, ATC, Cody M. O'Cain, MS, and Robert B. Anderson, MD*

Background: Studies routinely evaluate high ankle sprains in isolation, but recent data suggest that these injuries are often associated with concomitant pathology, potentially influencing return to full participation.

Hypothesis: In National Football League (NFL) players, isolated high ankle sprains are rare and syndesmosis injuries with concomitant pathology will result in increased time to return to full participation.

Study Design: Cross-sectional study.

Level of Evidence: Level 3.

Methods: Distal tibiofibular syndesmosis injuries sustained by NFL players between 2017 and 2019 were identified through NFL Injury Surveillance Database queries and verified with video analysis. Each injury underwent a comprehensive magnetic resonance imaging (MRI) review. Regression modeling was utilized to explore the influence of numerous imaging findings on time to return to full participation.

Results: There were 83 external rotation ankle injuries involving the syndesmosis. Isolated distal tibiofibular syndesmosis injuries were rare (n = 11; 13%) and more often associated with other ligamentous injury (deltoid ligament and lateral ligamentous complex) and/or fractures. Regression modeling resulted in clustering of 3 injury pattern groups for time to return to full participation across numerous imaging findings: syndesmosis injury-fracture combinations (250 days [interquartile range [IQR,] 142-266 days]), syndesmosis injury with complete deep deltoid tear or acute diastasis (175 days [IQR, 20-248 days]), and all other syndesmosis injuries (27 days [IQR, 18-46 days]).

Conclusion: In NFL athletes with external rotation ankle injuries, isolated distal tibiofibular syndesmosis injuries were rare and more often associated with concomitant pathology. Time to return to full participation was affected by an associated fracture and complete deep deltoid ligament tear or diastasis but no other relevant MRI variables such as lateral ligament complex involvement or the presence of osteochondral lesions or bone contusions.

Keywords: ankle; high ankle sprain; football; national football league; injury; magnetic resonance imaging; return to participation; video review

*Address correspondence to Robert B. Anderson, MD, OrthoCarolina, 2001 Vail Avenue - Suite 200B, Charlotte, NC 28207 (email: drrba1@gmail.com).
All authors are listed in the Authors section at the end of this article.

The following authors declared potential conflicts of interest: M.J.C. has received royalties or licenses from Arthrex, Stryker, and Smith & Nephew, consulting fees from Donjoy, and patents from Tenova Tenodesis Screw. M.M.H. has received consulting fees from the National Football League (NFL) and is a full-time employee of IQVIA. N.W. has received consulting fees from the NFL and is a full-time employee of the Green Bay Packers. E.M.S. has received consulting fees from the NFL and is a full-time employee of Biocore. C.M.O. has received consulting fees from the NFL and is a full-time employee of Biocore. R.B.A. has received royalties or licenses from Stryker and Artelon, and consulting fees from Stryker, Envois, Arthrex, Artelon, OsteoRemedies, and Nuvasive.
DOI: 10.1177/19417381241253223
© 2024 The Author(s)

The distal tibiofibular syndesmosis is a joint formed between the distal tibia and fibula by ligaments including the anterior inferior tibiofibular ligament (AITFL), the posterior inferior tibiofibular ligament (PITFL), the inferior transverse ligament, and the interosseous ligament and membrane (IOM).[7] The classically described mechanism of injury to the syndesmosis leading to a "high ankle sprain" is an external rotation and hyperdorsiflexion moment about the ankle.[2] In American football, a direct blow to the leg of a player who is prone with their foot held in external rotation or a force to the lateral aspect of the knee while a player's foot is planted in external rotation are purported mechanisms of injury.[2]

High ankle sprains in professional National Football League (NFL) players are thought to be relatively common.[1,3,4,17,21] In an analysis of NFL Combine participants, one-half had a history of ankle injuries, with about one-third of sprains classified as high ankle sprains.[21] In active NFL players across 10 seasons, there were 533 high ankle sprains in 498 players, 89.7% of whom returned to play after 80.5 days on average.[3] In another study, the 1-season time loss injury risk for NFL players with high ankle sprains was found to be 3.8%, with a total average injury burden per year of 5206 days, with a median of 21 days for each injury.[17] Interestingly, in 17 NFL players with high ankle sprains, MRI findings of the syndesmosis itself were not correlated significantly with time to return to play (RTP).[8] Another study evaluated 43 NFL athletes and found that complete syndesmosis injury with involvement of the deltoid ligament was associated with a higher likelihood of missed time compared with injuries involving the syndesmosis only.[25] Furthermore, syndesmosis injuries combined with lateral ankle sprain (LAS) were associated with more missed practices.[25] Neither study included syndesmosis injuries associated with fractures.[14]

These studies suggest that distal tibiofibular syndesmosis injuries are often associated with other concomitant pathology outside the syndesmosis itself that influence return to full participation in the NFL. The purpose of the current study was to evaluate external rotation ankle injuries involving the syndesmosis in NFL athletes and correlate imaging findings with time to return to full participation. We hypothesized that isolated high ankle sprains would be rare and that syndesmosis injuries with concomitant pathology would result in increased time to return to full participation.

METHODS

Study Design

This was a retrospective cross-sectional study that was granted approvals by the Mount Sinai School of Medicine Institutional Review Board (Project: STUDY-18-NFL17-MOD004) and the NFL Players Association (NFLPA) Player Scientific and Medical Research Protocol.[16]

Patient Population and Selection

The NFL Injury Surveillance database was queried to identify all external rotation ankle injuries during the 2017 to 2019 NFL pre-, regular-, and postseasons.[5] Clinical impression codes were utilized to ensure complete capture of all external rotation ankle injuries diagnosed by club medical staff and included the following diagnoses: "deltoid ligament sprain," "high ankle sprain," "ankle dislocation," "acute ankle fracture (excluding stress fractures) ," and "acute fibula fracture (excluding stress fracture) ." Isolated LAS with a prolonged period of missed time were also included due to suspicion for potential high ankle sprain involvement. These were defined as isolated LAS in the 90th percentile for days missed (>25 days) or an injury from the 2019 season with an unknown return date (still out due to injury).

Injuries captured by the queries were included only if they occurred in games, resulted in missed time from full participation, and/or were the result of any mechanism (including direct contact, indirect contact, and noncontact). In addition, to be included in the analysis, all injuries had to be clearly visible in at least 1 source of video footage derived from the NFL Vision game video archival system with adequate visualization to confirm external rotation of the foot relative to the tibia, with or without associated extreme dorsiflexion, as the probable mechanism of injury. Players with concomitant musculoskeletal injuries were rare, and the timing of return to full participation was recorded for the external rotation ankle injury specifically. Imaging, including magnetic resonance imaging (MRI) and either plain films or computed tomography (CT) had to be available within 30 days of injury onset. Injuries where external rotation ankle injury pathology was not apparent on imaging were excluded.

Imaging Review

MRI scans of each injury were reviewed by 3 authors, including a board-certified fellowship-trained musculoskeletal radiologist and 2 board-certified orthopaedic surgeons. MRI data were garnered from multiple different locations utilizing a wide variety of MRI scanners, providing a diverse spread of image quality when factoring in spatial resolution, contrast resolution, field of view (FOV), signal-to-noise ratio, and protocoled sequences. Most images included some combination of T1-weighted images with fluid-sensitive images (T2-weighted, proton density-weighted, and/or short tau inversion recovery [STIR]) in the axial, coronal, and sagittal planes.

Syndesmosis was analyzed as 3 separate components: AITFL, PITFL, and IOM. Each ligament component was documented in a standardized Excel Spreadsheet (Microsoft) as "normal," "partial tear," or "complete tear." MRI findings of ligamentous injury included periligamentous edema denoting an acute injury, intrasubstance increased T2 signal with mild morphologic irregularity denoting a partial tear, and severely disrupted ligament morphology or a gap in the ligament defining a complete tear. When applicable, syndesmotic injury was graded using a modified West Point classification scale, with grade 1 demonstrating no radiographic diastasis at the syndesmosis or mortise and injury isolated to the AITFL, grade 2 demonstrating no radiographic diastasis and injury involving both the AITFL

and IO, and grade 3 demonstrating radiographic diastasis with injury completely throughout the syndesmosis.[6] In addition, a subjective assessment was recorded of any distal IOM injury as "mild," "moderate," or "severe" based on the extent of surrounding soft tissue edema and any morphologic irregularity. A minority of these MRI studies provided a larger FOV extending into the proximal calf, giving greater coverage of the IOM.

Concomitant pathology was also documented and graded as "partial tears" or "complete tears" for the lateral collateral ligament complex separated into the anterior talofibular ligament (ATFL), calcaneofibular ligament (CFL), and posterior talofibular ligament (PTFL), and similarly for the deltoid ligament complex, separated into deep and superficial fibers. Coexistent tendon pathology was documented for the posterior tibial tendon (PTT), flexor hallucis longus tendon (FHL), and peroneal tendons as "tear/rupture," "tenosynovitis," or "subluxation." Osteochondral lesions (OCLs), defined on MRI scans as subchondral cysts, focal subchondral marrow edema, or chondral/subchondral disruptions were recorded when present and localized to either the talar dome or tibial plafond. Bone contusions defined on MRI scans as ill-defined regions of marrow edema were recorded when present and localized to the medial or lateral malleoli, talus, or distal tibia. Fracture lines and static diastasis (whether on radiographs or MRI scans) were documented when present. External rotation stress views and dynamic weightbearing radiographs or CT may have been obtained, but were not utilized in this study.

Management and Return to Full Participation

For each external rotation ankle injury, the date of removal from play and date of return to full participation was recorded by team medical staff from which time to return to full participation was calculated. Medical staff record the return to full participation date regardless of the timing in the season, and the return to full participation date is defined as the date the player resumes or would be able to resume full participation without restriction. If the injury required surgery, it was documented with any corresponding Current Procedural Terminology (CPT) code(s). Curation of data is composed of a variety of quality control checks including review of injury data with a regular team certified athletic trainer (ATC) follow-up to assure completeness of reporting; frequent training sessions to assure standardized, consistent and accurate data entry; and validation with external public media reports and sources.[5]

Injury Pattern Classification and Statistical Analyses

Descriptive statistics including raw counts (percentage), means and standard deviations, and medians (interquartile range [IQR]) were reported for different patterns of external rotation ankle injuries, the frequency of operative management, and return to full participation. To identify meaningful pathology groupings, forward, stepwise, and backward linear regression were utilized to explore the influence of imaging findings on time to return to full participation after an external rotation ankle injury. Candidate variables included those collected as described above, all of which were categorical variables. A significance level of 0.15 was used for both entry into the model and for a variable to remain in the model.[26] Descriptive statistics for days missed due to injury were then compared in a post hoc fashion to confirm regression modeling groupings. All statistics were computed utilizing the statistical software program SAS Version 9.4 (SAS Institute Inc).

RESULTS

Study Population

A total of 550 injuries were identified from the original database query for potential external rotation ankle injuries. After applying the aforementioned inclusion/exclusion criteria, 108 were included for imaging analysis (Figure 1).

Syndesmosis Injury Patterns

Of the 108 injuries evaluated and reviewed, 83 (n = 83; 76.9%) were classified as syndesmosis injuries with or without concomitant sprains or fractures (Table 1). Isolated syndesmosis injuries or high ankle sprains (n = 11; 13%) were less common than syndesmosis injuries combined with other concomitant sprains (n = 65; 78%). Syndesmosis injuries associated with a fracture were the least common (n = 7; 8%) and typically required surgical fixation (n = 5; 71%). About one-fifth (n = 11; 17%) of syndesmosis injury-sprain combinations and one-tenth of isolated syndesmosis injuries (n = 1; 9%) required surgery.

Of the 11 isolated high ankle sprains, only 1 (n = 1; 9%) demonstrated complete tearing of all components of the syndesmosis including the AITFL, PITFL, and IO. There were 9 (n = 9; 14%) complete tears in the syndesmosis injury-sprain combination group and 3 (n = 3; 43%) complete tears in the syndesmosis injury-fracture combination groups. Syndesmosis injury-fracture combinations were associated with a higher frequency of moderate or severe distal IOM injury (n = 5; 71%) as well as frank diastasis (n = 1; 14%) compared with isolated syndesmosis injury and syndesmosis injury-sprain combinations.

Around one-third of all evaluated injuries demonstrated bone contusions (n = 29; 35%). Distal tibia (n = 2; 3%) and medial malleolus (n = 1; 2%) bone contusions were reported only in the syndesmosis injury-sprain combination group. Bone contusions of the talus were also more frequent among syndesmosis injury-sprain combinations (n = 15; 23%). Posterior malleolus bone contusions were more common in the syndesmosis injury-fracture combination group, particularly among Weber C fractures (n = 2; 29%).

A total of 20% of injuries (n = 17) had associated OCLs. Tibial OCLs were most common in the syndesmosis injury-sprain combination group (n = 5; 8%), most commonly among syndesmosis injuries with a concomitant deltoid ligament sprain and LAS (n = 4; 13%). OCLs of the talus were most common among the syndesmosis injury-fracture combination group (n = 4; 57%) (Table 2).

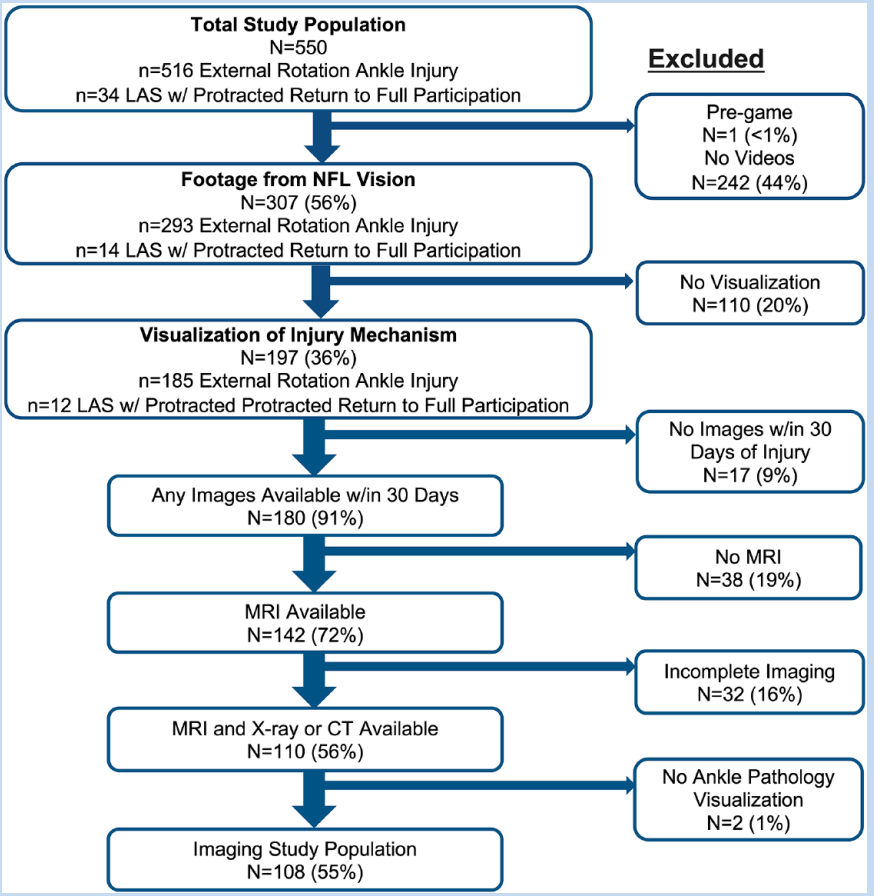

Figure 1. Syndesmosis injury MRI study population, National Football League, 2017-2019. CT, computed tomography; LAS, lateral ankle sprain; MRI, magnetic resonance imaging; NFL, National Football League.

Injury Pattern Predictors of Return to Full Participation

The overall median time to return to full participation after a high ankle sprain injury was 30 days (IQR, 19-73 days). Among the candidate variables included in our prediction models, variables that predicted the number of days missed were presence of fracture, presence of diastasis, presence of complete deltoid tear, and presence of PTT involvement. The presence of fracture, presence of diastasis, and presence of complete deltoid tear were significant predictors of more days missed due to injury, and presence of PTT involvement was a significant predictor of fewer days missed due to injury. Subsequently, 3 groups of syndesmosis injuries were created, including syndesmosis injury-fracture combinations, syndesmosis injuries with complete deep deltoid tear and/or acute diastasis, and all other syndesmosis injuries (Table 3). PTT involvement was found to be highly correlated with roster position, and clinical rationale for why PTT involvement would otherwise meaningfully reduce the number of days missed could not be determined and therefore was not included in the final groupings. A 1-way analysis of variance demonstrated significance among the 3 groups across return to full participation times ($P < 0.01$).

DISCUSSION

In this study of 83 external rotation ankle injuries in NFL players, isolated distal tibiofibular syndesmosis injuries were rare and were often associated with other ligamentous injury and/or fractures. Not surprisingly, syndesmosis injuries associated with fractures carried a higher frequency of moderate or severe distal IOM injury as well as frank diastasis and were more likely to undergo operative fixation. One-third of all injuries were associated with bone contusions and one-fifth with OCLs, with location of the pathology demonstrating a predilection for certain injury patterns. When assessing increased time to return to full participation, stepwise linear regression of all imaging variables resulted in clustering of 3 groups: syndesmosis injury-fracture combinations, syndesmosis injury with complete deltoid tear or acute diastasis, and all other syndesmosis injuries. Among these groups, syndesmosis injury-fracture combinations demonstrated the longest time to return to full participation.

Table 1. Syndesmosis injury: surgery incidence by pathology type, NFL, 2017-2019 (n = 83)

	Number of Injuries		Surgery	
	N	%	N	%
Isolated syndesmosis injury	11	13	1	9
Syndesmosis injury	11	13	1	9
Syndesmosis injury-sprain combinations	65	78	11	17
Syndesmosis injury and deltoid ligament sprain	11	13	1	9
Syndesmosis injury and LAS	24	29	3	13
Syndesmosis injury and deltoid ligament sprain and LAS	30	36	7	23
Syndesmosis injury-fracture combinations	7	8	5	71
Weber C ankle fracture and syndesmosis injury and deltoid ligament sprain	1	1	1	100
Weber C ankle fracture and syndesmosis injury and deltoid ligament sprain and LAS	2	2	2	100
Maisonneuve ankle fracture and syndesmosis injury and LAS	1	1	1	100
Maisonneuve ankle fracture and syndesmosis injury and deltoid ligament sprain	3	4	1	33
Total	83	100	17	20

LAS, lateral ankle sprain; NFL, National Football League.

Large epidemiological studies of NFL athletes often report "high ankle sprains" as a single entity without mention of concomitant pathology.[3,4,17] Our data suggest that only 13% of external rotation ankle injuries result in isolated injuries to the syndesmosis. Previous literature also often separate and compare syndesmosis and LAS,[23] but, in our study population, syndesmosis and LAS were seen concomitantly in over two-thirds (71%) of all injuries (excluding fractures). These data are similar to a previous MRI study of NFL players with syndesmosis injuries demonstrating that 44% of players had concomitant injury to the ATFL and 28% to the CFL.[25] Similarly, the deltoid ligament was implicated in 54% of all syndesmosis injuries (excluding fractures). Cadaveric studies examining external rotation injuries suggest that the deltoid is highly implicated in injury propagation (15 of 17 syndesmotic injuries).[18] The deltoid ligament is a well-known stabilizer of the syndesmosis in the coronal plane and is associated with disruption with at least 2 compromised syndesmotic ligaments,[19] which can result in instability and diastasis.[20] In American football players, infolding and retraction of an avulsed deltoid ligament complex after an ankle fracture, Maisonneuve injury, or severe high ankle sprain can be a source of persistent pain, instability, increased medial clear space, and malreduction, which is amenable to repair with robust outcomes.[9,10] In the current study, the nonfat suppressed coronal T1 sequence was vital for identifying these injuries, especially partial tears.

Syndesmosis injury propagation sequence and concomitant pathology is reliant largely on position of the foot and ankle at time of an external rotation injury.[18,22] When the ankle is in a neutral or dorsiflexed position, an external rotation force appears to cause injury in sequence to the superficial deltoid ligament, syndesmosis, interosseous membrane, and then fibula.[18] Any involvement of plantar-flexion may create stress across the lateral ligaments.[18] In addition, the addition of supination or pronation can cause injuries in a predictable pattern as well, which was first recognized, described, and graded by Lauge-Hansen.[14] In supination-external rotation (SER) injuries, the AITFL is torn or avulsed first, followed by displacement of the talus and fracture of the fibula, tearing of the PITFL or fracture of the posterior malleolus, and then tearing of the deltoid ligament or avulsion of the medial malleolus. With pronation-external rotation (PER) ankle injuries, the deltoid ligament is ruptured or there is an avulsion fracture of the medial malleolus first, followed by tearing of the AITFL with extension into the IOM, leading to a fibula fracture above the talotibial joint and then tearing of the PITFL or a fracture of the posterior malleolus. In these external rotation ankle fracture injuries, many have concomitant OCLs of the talar dome (61%) compared with the tibial plafond (6%) and articular surfaces of the medial and/or lateral malleoli (12%),[15] a pattern also seen in our study where OCLs of the talus were seen more frequently with syndesmosis injury-ankle fracture combinations.

Table 2. Syndesmosis injury MRI: interosseous, bone contusions, OCL, and diastasis, NFL, 2017-2019 (n = 83)

	Interosseous								Bone Contusions										OCL							
	None		Mild		Moderate		Severe		None		Distal Tibia		Medial Malleolus		Posterior Malleolus		Talus		None		Tibial		Talar		Diastasis	
	N	%	N	%	N	%	N	%	N	%	N	%	N	%	N	%	N	%	N	%	N	%	N	%	N	%
Isolated syndesmosis injury	4	36	5	45	1	9	1	9	7	64	0	0	0	0	2	18	2	18	9	82	0	0	2	18	1	9
Syndesmosis injury	4	36	5	46	1	9	1	9	7	64	0	0	0	0	2	18	2	18	9	82	0	0	2	18	1	9
Syndesmosis injury-sprain combinations	19	29	26	40	15	23	5	8	44	68	2	3	1	2	3	5	15	23	54	83	5	8	6	9	5	8
Syndesmosis injury and deltoid ligament sprain	2	18	6	55	3	27	0	0	8	73	1	9	0	0	1	9	1	9	10	91	0	0	1	9	3	27
Syndesmosis injury and LAS	8	33	7	29	7	29	2	8	17	71	0	0	1	4	0	0	6	25	21	88	1	4	2	8	0	0
Syndesmosis injury and deltoid ligament sprain and LAS	9	30	13	43	5	17	3	10	19	63	1	3	0	0	2	7	8	27	23	77	4	13	3	10	2	7
Syndesmosis injury-fracture combinations	2	29	0	0	1	14	4	57	3	43	0	0	0	0	2	29	2	3	3	43	0	0	4	57	1	14
Weber C ankle fracture and syndesmosis injury and deltoid ligament sprain	0	0	0	0	0	0	1	100	0	0	0	0	0	0	1	100	0	0	1	100	0	0	0	0	0	0
Weber C ankle fracture and syndesmosis injury and deltoid ligament sprain and LAS	1	50	0	0	0	0	1	50	0	0	0	0	0	0	1	50	1	50	0	0	0	0	2	100	0	0
Maisonneuve ankle fracture and syndesmosis injury and LAS	0	0	0	0	0	0	1	100	1	100	0	0	0	0	0	0	0	0	0	0	0	0	1	100	0	0
Maisonneuve ankle fracture and syndesmosis injury and deltoid ligament sprain	1	33%	0	0%	1	33%	1	33%	2	67%	0	0%	0	0%	0	0%	1	33%	2	67%	0	0%	1	33%	1	33%

LAS, lateral ankle sprain; MRI, magnetic resonance imaging; NFL, National Football League; OCL, osteochondral lesion.

Table 3. Syndesmosis injury MRI pathology group analysis, NFL, 2017-2019 (n = 83)

	N	%	Time to Return to Full Participation Median, Days (IQR)
Group 1. Syndesmosis injury-fracture combinations	7	8	250 (142-266)
Group 2. Syndesmosis injury with complete deep deltoid tear or acute diastasis	10	12	175 (20-248)
Group 3. All other syndesmosis injuries	66	80	27 (18-46)

IQR, interquartile range; MRI, magnetic resonance imaging; NFL, National Football League.

One-quarter of NFL patients in a previous syndesmosis imaging study had bony contusions and one-quarter had OCLs.[25]

RTP data after distal tibiofibular syndesmosis injuries have been published, but detail regarding actual primary and concomitant pathology incurred has been lacking; the current study begins to rectify this deficiency of detail. For instance, utilizing publicly available data, DeFroda et al[3] identified NFL players with "high ankle sprains" between the 2009 to 2010 and 2019 to 2020 seasons and found that RTP rates were high at 89.7%. However, their study did not differentiate high ankle sprains that involved the deep deltoid ligament and/or lateral ligament complex and was based solely on public reports.[12] Their study also did not include syndesmosis injuries with associated fractures. One study from 2017 evaluated distal fibula fractures in NFL athletes and found unsurprisingly that those who had surgery missed significantly more days than players who did not,[28] and, furthermore, those with isolated distal fibula fractures had significantly fewer days missed than those with combined patterns (ankle dislocation, medial malleolus fracture, or distal tibia fracture). That study did not separate ankle fractures by mechanism (ie, SER or PER) and did not include any MRI data.

This is the largest study in NFL athletes to evaluate the entire spectrum of distal tibiofibular syndesmosis injuries via MRI. Stepwise regression analysis of multiple imaging variables in the current study demonstrated that syndesmosis injuries cluster into 3 groups of injuries based on return to full participation times, which included syndesmosis injuries with (1) associated fractures, (2) complete deep deltoid ligament tears/acute diastasis, and (3) all other syndesmosis injuries. Return to full participation times for the groupings above were likely correlated with frequency of operative management. Indications for operative management of syndesmosis injuries are variable. Stable syndesmosis injuries can be treated nonoperatively,[27] and most surgeons look at syndesmosis widening and medial clear space widening on plain films as sole indications for an unstable injury and the need for operative fixation.[11] Increased medial clear space widening of >5 mm can indicate deep deltoid ligament injury.[24] Syndesmosis injuries associated with fractures are typically managed operatively.[13] In our study, the majority of syndesmosis injuries with associated fractures underwent surgical fixation (n = 5; 71%) compared with one-fifth (n = 11; 17%) of syndesmosis injury-sprain combinations (including deltoid ligament tears) and one-tenth of isolated syndesmosis injuries (n = 1; 9%) requiring surgery.

While the strengths of this study are numerous, there are limitations to be noted. Although MRI evaluation of the syndesmosis has demonstrated high interrater reliability among musculoskeletal radiologists,[8] MRI data in the current study were reviewed by 3 authors, not independently but rather in tandem, which may have introduced biases. There was a wide range of MRI scanners and protocols utilized for these injuries. Most were 1.5 T and 3 T magnets, but it is unknown whether lesser strength scanners, such as 0.2 T, were utilized. Second, while there are numerous quality control checks with regard to the NFL Injury Surveillance Database,[5] it is possible there could have been data errors or data not captured by the current study. For instance, if a patient had a surgery performed at an outside institution or the operative report was uploaded as an attachment as opposed to an actual entry it may have been omitted. Given the desire to have video evidence of an external rotation ankle injury, injuries sustained in practices were not included. Only the 2017 to 2019 seasons were analyzed due to feasibility of gathering images and live video at the time of study initiation. In addition, there are numerous factors that affect return to full participation and operational definitions vary. This study did not evaluate the indications for surgery, surgical technique, implants, or postoperative RTP protocols in the included athletes. Lastly, these data are limited to high level, elite athletes and may not be generalizable to the general population.

CONCLUSION

In 83 NFL athletes with external rotation ankle injuries, isolated distal tibiofibular syndesmosis injuries were rare and were more often associated with concomitant ligamentous injury (deltoid and lateral ligament complex) and/or fractures. Time to return to full participation was affected by the presence of an associated fracture or complete deep deltoid ligament tear/diastasis, but no other relevant MRI variables.

AUTHORS

Andrew W. Kuhn, MD (Department of Orthopaedic Surgery, Washington University in St. Louis, St. Louis, Missouri); **Michael J. Coughlin, MD** (Department of Orthopaedic Surgery, University of California - San Francisco, San Francisco, California); **Shane J. McGonegle, MD** (Gem State Radiology, Boise, Idaho); **Mackenzie M. Herzog, PhD, MPH** (IQVIA, Durham, North Carolina); **Nate Weir, MS, ATC** (Green Bay Packers, Green Bay, Wisconsin); **E. Meade Spratley, PhD** (Biocore LLC, Charlottesville, Virginia); **Cody M. O'Cain, MS** (Biocore LLC, Charlottesville, Virginia); and **Robert B. Anderson, MD** (Green Bay Packers, Green Bay, Wisconsin, Bellin Titletown Sports Medicine and Orthopedics, Green Bay, Wisconsin, and OrthoCarolina, Charlotte, North Carolina).

ACKNOWLEDGMENT

The authors would like to thank Erin Johnson, BS (IQVIA) and Alexandra Chretien, PhD (IQVIA) for their statistical assistance.

ORCID ID

Andrew W. Kuhn https://orcid.org/0000-0003-1836-7575

REFERENCES

1. Bedard G, Wyndham Lawrence D. Five-year trends in reported National Football League injuries. *Clin J Sport Med*. 2021;31(3):289-294.
2. Boytim MJ, Fischer DA, Neumann L. Syndesmotic ankle sprains. *Am J Sports Med*. 1991;19(3):294-298.
3. DeFroda SF, Bodendorfer BM, Hartnett DA, et al. Defining the contemporary epidemiology and return to play for high ankle sprains in the National Football League. *Phys Sportsmed*. 2022;50(4):301-305.
4. Desai SS, Dent CS, Hodgens BH, et al. Epidemiology and outcomes of ankle injuries in the National Football League. *Orthop J Sports Med*. 2022;10(6):23259671221101056.
5. Dreyer NA, Mack CD, Anderson RB, Wojtys EM, Hershman EB, Sills A. Lessons on data collection and curation from the NFL injury surveillance program. *Sports Health*. 2019;11(5):440-445.
6. Gerber JP, Williams GN, Scoville CR, Arciero RA, Taylor DC. Persistent disability associated with ankle sprains: a prospective examination of an athletic population. *Foot Ankle Int*. 1998;19(10):653-660.
7. Hermans JJ, Beumer A, de Jong TA, Kleinrensink GJ. Anatomy of the distal tibiofibular syndesmosis in adults: a pictorial essay with a multimodality approach. *J Anat*. 2010;217(6):633-645.
8. Howard DR, Rubin DA, Hillen TJ, et al. Magnetic resonance imaging as a predictor of return to play following syndesmosis (high) ankle sprains in professional football players. *Sports Health*. 2012;4(6):535-543.
9. Hsu AR, Anderson RB. Foot and ankle injuries in American football. *Am J Orthop (Belle Mead NJ)*. 2016;45(6):358-367.
10. Hsu AR, Lareau CR, Anderson RB. Repair of acute superficial deltoid complex avulsion during ankle fracture fixation in National Football League players. *Foot Ankle Int*. 2015;36(11):1272-1278.
11. Hunt KJ, Bartolomei J, Challa SC, et al. Significant variations in surgical construct and return to sport protocols with syndesmotic injuries: an ISAKOS global perspective. *J ISAKOS*. 2022;7(1):13-18.
12. Inclan PM, Kuhn AW, Troyer SC, Solomon GS, Matava MJ. Use of publicly obtained data in sports medicine research: a systematic review and bibliometric analysis. *Am J Sports Med*. 2024;52(5):1367-1373.
13. Jones CB, Gilde A, Sietsema DL. Treatment of syndesmotic injuries of the ankle: a critical analysis review. *JBJS Rev*. 2015;3(10):e1.
14. Lauge-Hansen N. Fractures of the ankle. II. Combined experimental-surgical and experimental-roentgenologic investigations. *Arch Surg* (1920). 1950;60(5):957-985.
15. Leontaritis N, Hinojosa L, Panchbhavi VK. Arthroscopically detected intra-articular lesions associated with acute ankle fractures. *J Bone Joint Surg Am*. 2009;91(2):333-339.
16. Mack C, Matava M, Zeidler K, Sills A, Solomon G. Clinical research in the National Football League: the player scientific and medical research protocol. *Curr Sports Med Rep*. 2020;19(5):168-174.
17. Mack CD, Kent RW, Coughlin MJ, et al. Incidence of lower extremity injury in the National Football League: 2015 to 2018. *Am J Sports Med*. 2020;48(9):2287-2294.
18. Mait AR, Forman JL, Nie B, et al. Propagation of syndesmotic injuries during forced external rotation in flexed cadaveric ankles. *Orthop J Sports Med*. 2018;6(6):2325967118781333.
19. Massri-Pugin J, Lubberts B, Vopat BG, Wolf JC, DiGiovanni CW, Guss D. Role of the deltoid ligament in syndesmotic instability. *Foot Ankle Int*. 2018;39(5):598-603.
20. Miller CD, Shelton WR, Barrett GR, Savoie FH, Dukes AD. Deltoid and syndesmosis ligament injury of the ankle without fracture. *Am J Sports Med*. 1995;23(6):746-750.
21. Mulcahey MK, Bernhardson AS, Murphy CP, et al. The epidemiology of ankle injuries identified at the national football league combine, 2009-2015. *Orthop J Sports Med*. 2018;6(7):2325967118786227.
22. Norkus SA, Floyd RT. The anatomy and mechanisms of syndesmotic ankle sprains. *J Athl Train*. 2001;36(1):68-73.
23. Osbahr DC, Drakos MC, O'Loughlin PF, et al. Syndesmosis and lateral ankle sprains in the National Football League. *Orthopedics*. 2013;36(11):e1378-1384.
24. Park SS, Kubiak EN, Egol KA, Kummer F, Koval KJ. Stress radiographs after ankle fracture: the effect of ankle position and deltoid ligament status on medial clear space measurements. *J Orthop Trauma*. 2006;20(1):11-18.
25. Sikka RS, Fetzer GB, Sugarman E, et al. Correlating MRI findings with disability in syndesmotic sprains of NFL players. *Foot Ankle Int*. 2012;33(5):371-378.
26. Steyerberg EW. *Clinical Prediction Models*. 1st ed. New York, NY: Springer-Verlag; 2009.
27. van Dijk CN, Longo UG, Loppini M, et al. Conservative and surgical management of acute isolated syndesmotic injuries: ESSKA-AFAS consensus and guidelines. *Knee Surg Sports Traumatol Arthrosc*. 2016;24(4):1217-1227.
28. Werner BC, Mack C, Franke K, et al. Distal fibula fractures in National Football League athletes. *Orthop J Sports Med*. 2017;5(9):2325967117726515.

For article reuse guidelines, please visit Sage's website at http://www.sagepub.com/journals-permissions.